

EFFCET OF DIETARY SUPPLEMENTATION WITH DIFFERENT LEVELS OF FENUGREEK SEEDS (*Trigonella foenum graecum*) ON SEMEN QUALITY AND HISTOLOGICAL TESTIS TRAITS OF JAPANESE QUAIL (*Coturnix coturnix japonica*)

Ahmed T. Taha

**Dept. of Animal Resources ,College of Agriculture ,University of Tikrit ,Iraq
Author correspondence E-mail :ahmedtaies @yahoo.com**

ABSTRACT

This study was conducted to evaluate the effect of the addition of fenugreek seeds (F.S) to the Japanese quail males ration on semen quality and testis histological traits. A total of 28 males (125 day old) divided into four groups (7 males/group) and treated as follow T1 =control group reared on standard ration,T2 = standard ration supplemented with 5gm F.S /kg , T3= standard ration supplemented with 10gm F.S /kg, T4= standard ration supplemented with 15gm F.S /kg . Semen samples were assessed after four weeks of treatment as regards ejaculation volume , spermatozoa motility ,viability and semen concentration and testis traits which involved testis weight , seminiferous tubules diameter(S.D), seminiferous tubules lumen diameter (L.D) germinal layer thickness (G.T) and germinal layer area(G.A) and seminiferous tubules lumen area (L.A) .

Results revealed that the treatment (T2,T3 and T4) resulted a significant ($p \leq 0.05$) improvement in ejaculation volume , spermatozoa motility ,viability and semen concentration in comparison with control group (T1) . The testis weight , seminiferous tubules diameter, germinal layer thickness and germinal layer area showed significant increase ($p \leq 0.05$)in fenugreek seeds groups as compared with control group. Seminiferous tubules lumen diameter and lumen area were increased significantly in control group as compared with the fenugreek seeds treatment .In conclusion , the supplementation of F.S to the Japanese quail males ration will improve semen quality traits and sustain the histological traits of the testis.

Keywords: Fenugreek, Japanese quail ,semen, testis histology.

Received for publication Oct. 12 , 2010 .
Accepted for publication Dec. 29 , 2010 .

INTRODUCTION

Fenugreek (*Trigonella foenum graecum* L.) is an annual plant from the family of Leguminosae, originate in India and native cultivated in south Europe, Northern Africa, India and Egypt and south of Iraq. It have many uses in medical purposes, fenugreek seeds have a great effect in relation to increasing lactation; also it helps to increase urine and menstruation in women. It helps also in rickets and anemia. Owing to the existence of mucilage, it helps relieve sore throat and is useful in the treatment of asthma and difficult breathing/Fenugreek is considered as an appetizer and helps in digestion. Fenugreek seeds have also been recognized as a potential source of diosgenin, a basic compound in the hemisynthesis of steroidal sapogenins such as cortisone and sex hormones (Brenac and. Sauvaire1996a,b).It use as a astrangents materials and antibloat (Chopra *et al* ,1982) , and used in animal feed (Cheij ,1984). However it used as a supplement to poultry feeding to lowering plasma total lipids and total cholesterol in Hubbard broiler chicks (Azouz ,2001) and improve antioxidant status and production performance in laying hens (Al katan 2006) . Fenugreek seeds improve the reproductive and physiological performance of broiler breeder males (Taha , 2008) , and revealed positive significant results of semen traits in aged broiler breeder males (Abdul –Rahman *et al* 2010) .

On the other hand Japanese quail is one of the most important laboratory animals, the efficiency of spermatogenesis in the Japanese quail has been estimated to be 92.5×10^6 sperm per gram of testis per day (Clulow and Janes ,1988) , Setchell (1978) refer to this production of semen occurs at temperature $40 \pm 1-1.5$ C°.the testis comparatively rich in lipid. In most species there about 20mg / gm wet weight and markedly high level of it was polyunsaturated fatty acid, therefore became susceptible to the damage induced by excessive reactive oxygen species (R O S) release (Cecil and Bakst ,1993).

Therefore the present study was designed to examine the ability of fenugreek seeds to improve the semen quality and testis histology characteristics in the Japanese quail males.

MATERIALS AND METHODS

This study was conducted at the Poultry Farm of Department of Animal Resources , College of Agriculture / Tikrit University , during the period from 5/1/2009 to 19/3/2009 , to determine the effect of addition of fenugreek seeds to the Japanese quail males ration on semen quality and the testis histology traits. A total of 28 males of Japanese quail 125 day old were divided into four

treatment groups with 7 males per treatment . experimental treatments were as follow :

First group – control group(T1): Birds fed standard ration without any additive .

Second group (T2) : Birds fed standard ration supplemented with 5gm F.S /kg of diet .

Third group (T3):Birds fed standard ration supplemented with 10gm F.S /kg of diet .

fourth group (T4) : Birds fed standard ration supplemented with 15gm F.S /kg of diet .

The birds housed in individual wire cages with (40 ×40 ×40 cm) and fed *ad libitum* with a diet containing 19.9 % crude protein and 2878 k cal metabolizable energy /kg of diet .

The semen was obtained from each male three times per week for two months after four weeks of treatment. The procedure adopted for semen collection from quails began by taking the male from cage and placing it on the left hand with the birds breast in the palm of the hand ,wing and legs were held up .The foam was removed from the cloacal gland by delicate squeezing of the gland with the thumb of left hand and the forefinger of right hand and collected semen by, using the abdominal massage modified method Burrows and Quinn (1937)

Semen volume was determined by scales class micropipette before and after collection semen by electron balance sensitive for four rank, mass and individual motility of sperm cells was estimated on percentage basis according to (Parker *et al* 1942), sperm viability expressed as percentage of dead sperm was analyzed using mixed of eosin and nigrosin stain ,the spermatozoa concentration was determined by using hemacytometer counting chamber (Bakst and Cecil ,1997) . At end of study the birds were slaughtered by cutting the jugular vein , testis were excised for histological and morphological analyses . The right and left test of each bird were weighed , right testis from three birds of each treatment were cut into serial cross sections 5mm in thickness and fixed in 10% neutral buffered formalin , fixed samples were processed and stained with hematoxylin and eosin stains (Luna ,1968) then used for the measurement of the seminiferous tubules diameter(S.D), seminiferous tubules lumen diameter (L.D) , germinal layer thickness (G.T) , germinal layer area (G.A) and tubules lumen area (L.A) by Olympus ocular stage micrometer.

STATISTICAL ANALYSIS

The statistical analysis of the data was performed using a completely randomized design (CRD) using the statistical analysis system (SAS , 2001). Duncan multiple range test was used to detect the significant differences among treatments means (Steel and Torrie,1980) .

RESULTS AND DISCUSSION

F.S. supplementation caused a significant increase ($p \leq 0.05$) in ejaculation volume , mass and individual motility and spermatozoa concentration in comparison with the control group, and a significant reduction in dead sperm percentage as compared with control group (Table 1) .

The increase in ejaculation volume in (F.S.) treatments may be due to the increase in thickness and area of germinal layer in seminiferous tubules ,or to increased testis weight (Etches ,2000), meanwhile the improvement of mass and individual motility may be correlated with the increase of spermatozoa concentration (Saeid and Al- Soudi , 1975) those authors found positive correlation between spermatozoa motility and concentration, or due to the decrease in dead spermatozoa percentage (Taha,2008). The decrease in dead spermatozoa percentage in fenugreek seeds treatments may be due to the potent antioxidant activity of (F.S), Fenugreek seeds had important role in improving the seminal plasma and testis tissue by lowering Malondialdehyde (MDA) level in it (Taha ,2008).The significant increase in spermatozoa concentration in fenugreek seeds treatments may be due to the effect of F.S increase the plasma concentration of FSH and LH hormones (Taha ,2008).

There was a significant increase ($p \leq 0.05$) for (F.S) treatments regarding body weight ,S.D, G.T and G.A , meanwhile a significant decreased in S.L and L.A in comparison with the control group (Table 2) .

A significant increase ($P \leq 0.05$) of live body weight in (F.S) treatments could be explained by the improvement in the feed efficiency in Japans quail when additive it to the ration (Roshdy,2006) . The increase in testis weight may be refers to the increase in body weight because it was found that there was positive correlation between testis weight and body weight (Etches ,2000).However the increase in testis weight and activity may be to reflection of the improvement of histological treats as S.D , G.A and G.T .

From figures (1,2,3,4) noted decreased in interstitial space (I) with fenugreek seeds treatments comparative with control group , whenever noted significantly increased in seminiferous tubules (S.D) , germinal layer thickness (G.T) and germinal layer area (G.A) in fenugreek seeds treatments . Seminiferous tubules

lumen diameter (L.D) and Someniferous tubules lumen area (L.A) increased in control treatment comparison with fenugreek seeds treatments the positive significantly effects for fenugreek seeds in testis histology may by related to ability of fenugreek seeds to reduced malondialdehyde (MDA) level and rising glutathione GSH level in testis tissues (Taha , 2008) .

It was concluded from this study that fenugreek seeds supplementation at level 10 or 15 gm /kg diet can improve the semen quality and testis histology traits in Japanese quail males .

Table 1 . *Effect of different levels of fenugreek seeds supplementation on some semen traits of Japanese quail males (means \pm SE) .*

| Traits | Treatments | | | |
|--|-----------------------|-----------------------|-----------------------|-----------------------|
| | T1/ Control | T2 /5gm F.S /Kg diet | T3 /10gmF.S /Kg diet | T4/15gm F.S /Kg diet |
| Ejaculation volume(μ l) | 14.08 \pm 0.33 b | 15.50 \pm 0.37 b | 20.50 \pm 0.35 a | 21.08 \pm 0.36 a |
| Mass motility(%) | 75.25 \pm 0.62 d | 81.58 \pm 0.56 c | 86.13 \pm 0.50 b | 88.86 \pm 0.43 a |
| Individual motility (%) | 77.44 \pm 0.61 c | 83.81 \pm 0.48 b | 86.80 \pm 0.40 a | 88.16 \pm 0.35 a |
| Dead sperm (%) | 22.41 \pm 0.58 a | 15.88 \pm 0.45 b | 12.66 \pm 0.34 c | 11.55 \pm 0.38 c |
| Sperm concentration ($\times 10^6$ /ml) | 1.22 \pm 0.027 d | 1.36 \pm 0.022 c | 1.88 \pm 0.043 b | 2.11 \pm 0.034 a |

Different letters within row means significant difference at ($P \leq 0.05$)

Table 2 . Effect of different levels of fenugreek seeds supplementation on body and testis weight and some histological testis traits of Japanese quail males (means \pm SE) .

| Traits | Treatments | | | |
|----------------------------|------------------------|-------------------------|------------------------|------------------------|
| | T1/ Control | T2 /5gm F.S /Kg ration | T3 /10gm F.S/Kg ration | T4/15gm F.S /Kg ration |
| Body weight(gm) | 170.58 \pm 5.01b | 178.50 \pm 4.47a b | 188.67 \pm 4.72 a | 184.87 \pm 4.89 a |
| Testis absolute weight(gm) | 3.84 \pm 0.51 b | 5.01 \pm 0.39 a | 5.30 \pm 0.32 a | 5.32 \pm 0.23 a |
| SD(micron) | 27.10 \pm 0.46 b | 28.65 \pm 0.55 a | 29.11 \pm 0.48 a | 28.58 \pm 0.41 a |
| LD(micron) | 13.18 \pm 0.32 a | 11.51 \pm 0.37 b | 9.98 \pm 0.40 c | 9.51 \pm 0.47 c |
| TG(micron) | 15.46 \pm 0.48 b | 15.58 \pm 0.48 b | 19.13 \pm 0.56 a | 19.06 \pm 0.47 a |
| GA(micron) ² | 474.52 \pm 18.54 b | 512.94 \pm 22.63 b | 589.40 \pm 21.80 a | 569.57 \pm 16.94 a |
| LA(micron) ² | 138.89 \pm 6.80 a | 107.37 \pm 6.81 b | 81.99 \pm 6.35 c | 76.23 \pm 7.84 c |

Different letters within row means significant difference at (P \leq 0.05)

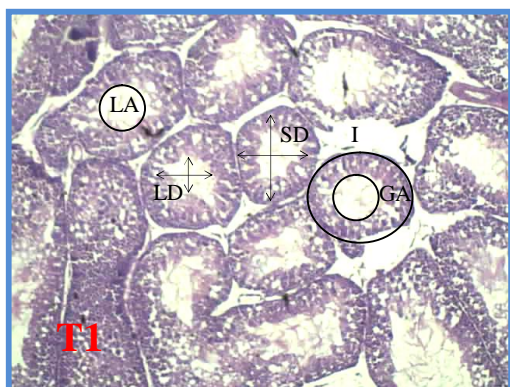


Figure (1)

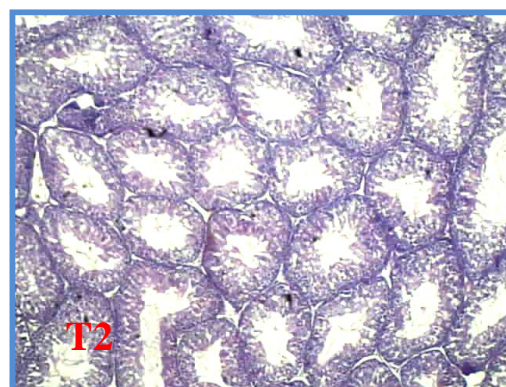


Figure (2)

Figure 1. Cross section of left testes of quail male stained with hematoxylin and eosin .Magnification is 40 for treatment (1)control group

seminiferous tubules diameter(S.D), seminiferous tubules lumen diameter (L.D) , germinal layer thickness (G.T) , germinal layer area (G.A) , tubules

Figure 2. Cross section of left testes of quail male stained with hematoxylin and eosin .Magnification is 40 for treatment (2) T2 =fed standard ration supplemented with 5 gm F.S /kg of diet,.

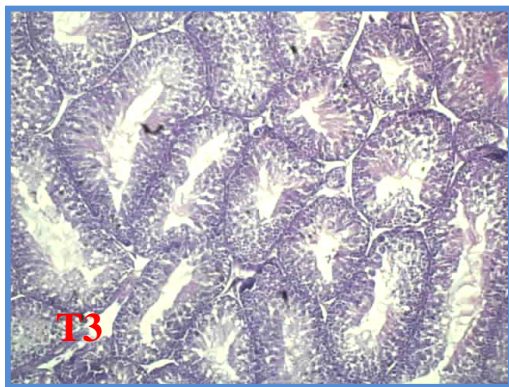


Figure (3)

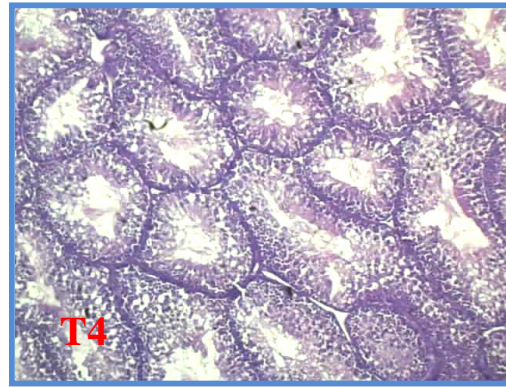


Figure (4)

Figure 3 . Cross section of left testes of quail male stained with hematoxylin and eosin .Magnification is 40 for treatment T3=fed standard ration supplemented with 10gm F.S /kg .

Figure 4 . Cross section of left testes of quail male stained with hematoxylin and eosin .Magnification is 40 for treatment T4=fed standard ration supplemented with 15gm F.S /kg.

REFERENCES

- Abdul- Rahman ,S . Y . , K. H . Sultan and A .T .Taha . 2010. The effect of use of fenugreek seeds on the reproductive performance of aged broiler breeder males .J.of Tikrit University For Agricultural Sciences , no(2) vol . 10 . p 156-163
- Alkatan , M . M . 2006 . Effect using some antioxidants on production performance and some physiological characters in laying hens. Ph.D. Thesis. College of Agriculture and Forestry , University of Mosul . Iraq.
- Azouz, H.M.M. 2001. Effect of hot pepper and fenugreek seeds supplementation on broiler diets. Ph.D. Thesis, Poultry Nutrition Dept. Faculty of Agriculture, Cairo University.
- Bakst M.R, H.C Cecil (eds), 1997. Techniques for semen evaluation, semen storage, and fertility determination. Savoy, Illinois: PoultryScience Associates.
- Brenac, P. and Y. Sauvaire 1996a. Chemotaxonomic value of sterols and steroidal sapogenins in the genus *Trigonella*. *Biochem. Syst. Ecol.*, 24: 157-164.
- Brenac, P. and Y. Sauvaire 1996b. Accumulation of sterols and steroidal sapogenins in developing fenugreek pods: possible biosynthesis in situ. *Phytochemistry*, 41: 415-422.
- Burrows, W. H. , and J . P . , Quinn, 1937. The collection of spermatozoa from the domestic fowl and turkey . *Poultry Sci .*, 16 : 19-24.
- Cecil , H.C., and M.R.Bakst.1993. In vitro lipid peroxidation of turkey spermatozoa . *Poult . Sci.*72:1370-1378 .

- Cheij , R. 1984. McDonald Encyclopedia of medical plants . McDonald and Co., (publishers) Ltd, London , PP, : 209,309, 313.
- Clulow J. and R.C. Janes 1988. Studies of fluid and sperm transport in the extra testicular ducts of the Japanese quail .J. Anat 157 ,1-11
- Chopra, R. N. L . C. Chopra. , K . L. Honda and, L. D. kapur.1982. Chopras endogenous drag of India, Academic publisher , Calcutate , New Delhi , India. P. 582.
- Etches , R. J . 2000.Reproduction in Poultry . University press , Cambridge
- Luna , L. G. , 1968 . Manual of histological staining methods of the armed forces institute of pathology. Mcgraw hill book copany , New York, pp . 38-39.
- Parker , J. E. , F. F. McKenzine and H. L. Kempster , 1942. Fertility in the male domestic fowl. Missori Agr. Exp, Res, Bulletin no. 374.
- Roshdy , A. R. 2006. Improving japans quail productivity under North Senai conditions .MSC thesis College Faculty of Environmental Agricultural Sciences Suez Canal University. Egypt
- Saeid , J. M . and K . A . AL – Souidi . 1975 . Seasonal variation in semen characteristics of White Leghorn , New Hampshire and indigenou chicken in Iraq . Br . Poult . Sci . 16: 97 – 102 .
- SAS, 2001. SAS User's Guide : Statistics Version 6th ed, SAS Instutite Inc., Cary NC.
- Setchell . B. P. 1978 . The mammalian testis. Paul Elek London .
- Steel ,R.G.D., and J.H. Torrie , 1980 . Principles and procedures of statistics .2nd . Ed . Mc .Graw- Hill Book Co., Inc. New York , Ny .
- Taha ,A.T.2008.The role of vitamins A , C and fenugreek seeds in lowering the effect of oxidative stress effect on physiological and reproductive performance of broiler breeder males . Ph.D. Thesis. College of Agriculture and Forestry , University of Mosul . Iraq .
- Whittow , G.C. 2000 . Sturk's Avian Physiology. Fifth Edition academic press. Boston Newyork .

تأثير اضافة مستويات مختلفة بذور الحلبة (*Trigonella foenum graecum*) في
صفات السائل المنوي وصفات الخصية النسيجية لطيور السمان
(*Coturnix coturnix japonica*)

احمد طيس طه

قسم الثروة الحيوانية - كلية الزراعة - جامعة تكريت

الخلاصة

أجريت هذه الدراسة بهدف دراسة تأثير إضافة مستويات مختلفة من مسحوق بذور الحلبة إلى علائق طيور السمان في صفات السائل المنوي وصفات الخصية النسيجية . قسمت ٢٨ ذكرا من طيور السمان بعمر ١٢٥ يوما إلى أربعة مجاميع وبواقع (٧ طير / معاملة) وتمت معاملتها وفقا لما يأتي :
T1 = معاملة سيطرة غذيت على عليقة قياسية (بدون أي إضافة) ، T2 = غذيت على عليقة السيطرة + ٥ غم / كغم علف من مسحوق بذور الحلبة ، T3 = غذيت على عليقة السيطرة + ١٠ غم / كغم علف من مسحوق بذور الحلبة ، T4 = غذيت على عليقة السيطرة + ١٥ غم / كغم علف من مسحوق بذور الحلبة .
تم جمع عينات السائل المنوي بعد مرور ٢٨ يوم من المعاملة لدراسة صفات السائل المنوي الآتية حجم القذفة و الحركة الجماعية للنطف و حيوية النطف وتركيز النطف ، إضافة إلى صفات الخصية النسيجية المتمثلة بوزن الخصية و قطر النبيب المنوي و قطر تجويف النبيب المنوي وسمك ومساحة الطبقة الجرثومية ومساحة تجويف النبيب المنوي . أظهرت النتائج تفوقا معنويا ($p \leq 0.05$) لصالح المعاملات الثانية والثالثة والرابعة (معاملات الحلبة) مقارنة بمعاملة السيطرة في كل من حجم القذفة والحركة الجماعية للنطف وحيوية النطف إضافة إلى تركيز النطف) ، أما بالنسبة لصفات الخصية النسيجية فيلاحظ وجود تفوق معنوي ($p \leq 0.05$) لصالح معاملات الحلبة مقارنة بمعاملة السيطرة في الصفات الآتية وزن الخصية وقطر النبيب المنوي وسمك ومساحة الطبقة الجرثومية ، في حين وجد تفوق معنوي ($p \leq 0.05$) في كل من قطر ومساحة تجويف النبيب المنوي .
نستنتج من هذه الدراسة أن لإضافة مسحوق بذور الحلبة إلى علائق السمان القدرة على تحسين صفات السائل المنوي وصفات الخصية النسيجية .